

Whole Body Skeletal Anatomy

Difficulty: Medium

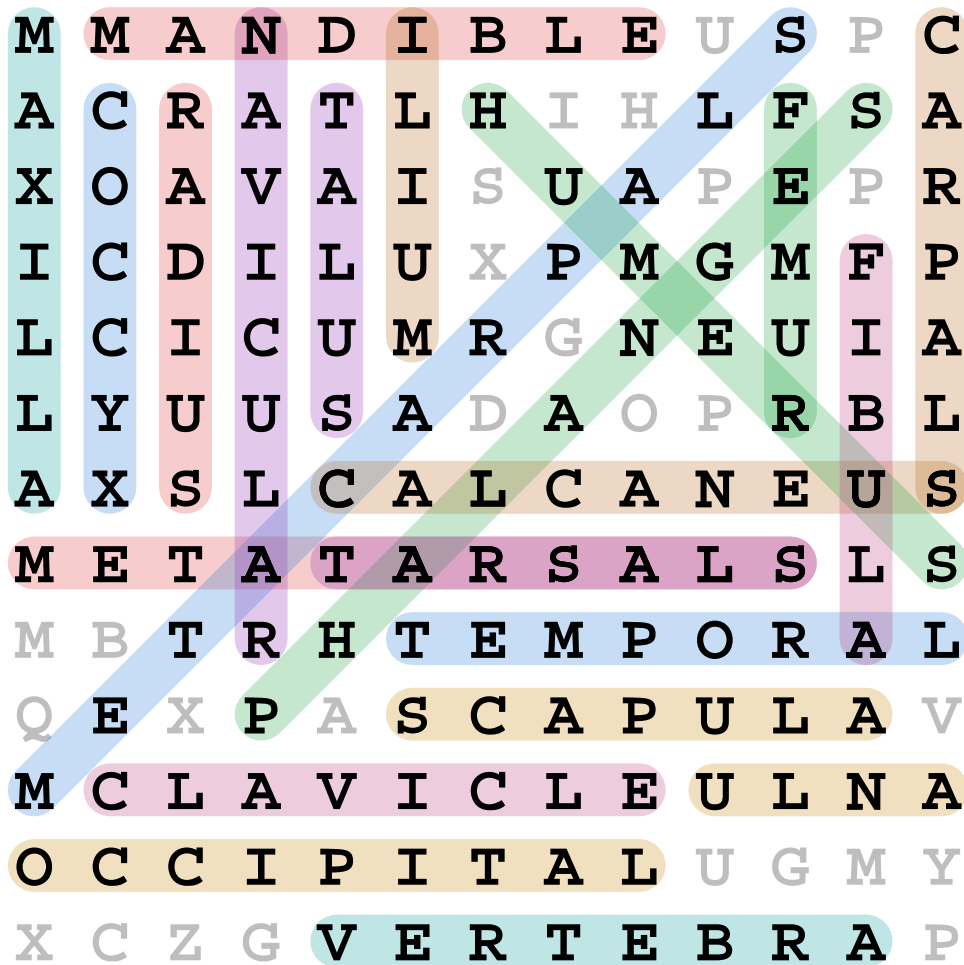
M M A N D I B L E U S P C
A C R A T L H I H L F S A
X O A V A I S U A P E P R
I C D I L U X P M G M F P
L C I C U M R G N E U I A
L Y U U S A D A O P R B L
A X S L C A L C A N E U S
M E T A T A R S A L S L S
M B T R H T E M P O R A L
Q E X P A S C A P U L A V
M C L A V I C L E U L N A
O C C I P I T A L U G M Y
X C Z G V E R T E B R A P

Find these words:

METATARSALS	METACARPALS	PHALANGES	CALCANEUS
NAVICULAR	OCCIPITAL	VERTEBRA	CLAVICLE
MANDIBLE	TEMPORAL	HUMERUS	CARPALS
TARSALS	SCAPULA	MAXILLA	FIBULA
RADIUS	COCCYX	FEMUR	ILIUM
TALUS	ULNA		

Whole Body Skeletal Anatomy - Answer Key

Difficulty: Medium



Words found:

METATARSALS	METACARPALS	PHALANGES	CALCANEUS
NAVICULAR	OCCIPITAL	VERTEBRA	CLAVICLE
MANDIBLE	TEMPORAL	HUMERUS	CARPALS
TARSALS	SCAPULA	MAXILLA	FIBULA
RADIUS	COCCYX	FEMUR	ILIUM
TALUS	ULNA		